Predictors of Non-Diagnostic Ultrasound Scanning in Children with Suspected Appendicitis

Suzanne Schuh, MD, FRCP(C), Carina Man, Adam Cheng, MD, FRCP(C), Amanda Murphy, MD, Arun Mohanta, CSDMS, Rahim Moineddin, PhD, George Tomlinson, PhD, Jacob C. Langer, MD, FRCS(C), and Andrea S. Doria, MD, PhD, MSc, FACR

Objective To determine predictors of diagnostically inaccurate ultrasound scanning for suspected appendicitis.
Study design Prospective emergency department cohort study of 263 previously healthy children 4 to 17 years of age undergoing ultrasound scanning. Ultrasound scanning results were interpreted as positive, negative, or equivocal for appendicitis and classified as diagnostically accurate and inaccurate. The main outcome measure was association between inaccurate ultrasound scanning and age, sex, body mass index percentiles, pain duration, white blood cell count, Faces Pain Score-Revised, clinical probability of appendicitis, and ultrasound scanning operator.
Results Of the 263 patients, 95 ultrasound scanning examinations were read as positive, 76 as negative, and 92 were equivocal. A total of 162 (61.6%) ultrasound scanning examinations were accurate (TP86, TN76), and 101 (38.4%) ultrasound scanning examinations were inaccurate (FP88, FN13). Children with body mass index percentiles ≥85 and clinical probability of appendicitis ≤50% had 58.1% probability of inaccurate ultrasound scanning examination (odds ratio, 2.48; 95% confidence interval, 1.48-2.78). In lean children, diagnostic accuracy of the screening ultrasound scanning examination with second ultrasound scanning or clinical reassessment was 93% versus 83% in the obese children (95% confidence interval of the difference, 1-19%).
Conclusion Screening ultrasound scanning for pediatric appendicitis has suboptimal accuracy, particularly in obese children with a low likelihood of appendicitis who should not routinely undergo ultrasound scanning. However, when followed by a second ultrasound scanning or a clinical reassessment, it offers high diagnostic accuracy in lean children. *(J Pediatr 2011;158:112-8)*.

Acute appendicitis remains the most common reason for abdominal surgery in children.[1] Correct diagnosis remains challenging,[2] yet accurate and timely identification of appendicitis is critical because a diagnostic delay may result in increased morbidity.[3]

Because of its numerous advantages, ultrasound scanning has become a widespread initial diagnostic tool in children with suspected appendicitis.[4-7] However, it may be inconclusive because even the most experienced sonographers occasionally fail to visualize the appendix,[8,9] particularly when it is normal, retro-cecal, perforated, or when the inflammation only involves the distal tip.[10,11] Because non-visualization of the appendix does not rule out appendicitis,[12] children with inconclusive ultrasound scanning results often undergo a computerized tomography (CT) scan examination.[9,13] Furthermore, inconclusive ultrasound scanning results frequently results in lengthy emergency department (ED) stays and may contribute to delayed diagnosis and increased perforation rates.[10,14] Although a small pediatric study has identified a correlation between overweight status and difficulty in detecting the appendix,[15] no children with appendicitis participated, and a cutoff body mass index (BMI) justifying alternate imaging could not be identified. Furthermore, other clinical factors may also contribute to inaccurate ultrasound scanning results, and these have not been previously identified. Children with a high probability of inaccurate screening ultrasound scanning results may not be suitable candidates for this imaging modality, but may benefit from alternative screening imaging methods such as a CT scanning.

The primary objective of this study was to determine clinical predictors associated with diagnostically inaccurate ultrasound scanning results in children 4 to 17 years of age who come to our ED with suspected appendicitis. Secondary objectives were to compare the groups with accurate and inaccurate ultrasound scanning results for prolonged stay in hospital, frequency of definitive manage-

BMI	Body mass index
BMI-FAP	Body mass index for age percentiles
CI	Confidence interval
CPA	Clinical probability of appendicitis
CT	Computerized tomography
ED	Emergency department
MRI	Magnetic resonance imaging
OR	Odds ratio

From the Divisions of Pediatric Emergency Medicine (S.S., A.C.), Diagnostic Imaging (C.M., A.Mohanta, A.D.), and Pathology (A.Murphy), The Hospital for Sick Children, Toronto, Ontario, Canada; British Columbia Children's Hospital (A.C.), University of British Columbia, British Columbia, Vancouver, Canada; and Departments of Pediatrics (S.S., A.C.), Surgery (J.L.), and Family Medicine (R.M., G.T.), University of Toronto, Toronto, Ontario, Canada

Funded by The Hospital for Sick Children Foundation (grant XG06-050). A.D. received a Career Development Award from the Canadian Child Health Clinician-Scientist Program (2006-2010). The authors declare no conflicts of interest.

Presented in part as a platform presentation at the Pediatric Academic Societies meeting in Baltimore, MD, May 2009.

 10.1016/j.jpeds.2010.07.035

ment decision after the screening ultrasound scanning, and the rate of second imaging.

Methods

We conducted a prospective consecutive cohort study of children 4 to 17 years of age who came to our ED between February 2007 and December 2008 during study coverage times and underwent ultrasound scanning for suspected appendicitis ordered by the ED staff physician. In defining exclusion criteria, we concentrated on children in whom the diagnosis of appendicitis would be difficult because of pre-existing conditions or concurrent pharmacotherapy and children whose imaging had been performed/interpreted elsewhere. Children with co-morbidities such as earlier abdominal or pelvic surgery, malignancy, or chronic systemic disease were excluded, as were children taking oral corticosteroids or antibiotics. Families with a poor command of the English language did not participate. The study was approved by the research ethics board of our institution.

Children who came to our ED with abdominal pain were assessed, and those in whom the ED staff suspected appendicitis as a diagnostic possibility were screened for eligibility by one of 4 trained research assistants. The research assistants obtained written informed consent from all participating patients/families and acquired relevant demographic and clinical information with the assistance of the ED staff/fellow. Before ultrasound scanning, the ED staff also used the clinical information and laboratory data to estimate the clinical probability of appendicitis in each child on a visual analog score ranging from 0% to100%. Thereafter, the children were taken for an ultrasound scanning examination, performed by an experienced sonographer in consultation with a staff radiologist during the day and by trained diagnostic imaging fellows during evenings, nights, and weekends.

Before the study, all diagnostic imaging fellows received additional education on the details of the ultrasound scanning technique in detecting the appendix and identification of the sonographic signs in the appendix and surrounding tissues suggestive of appendicitis and lack thereof. Because these trainees may have less experience than sonographers, their image acquisition may be a predictor of non-diagnostic ultrasound scanning results.

High-resolution (frequency range, 7-13 MHz), linear array ultrasound scanning transducers were used (Philips iU 22, Philips Electronics systems, Bothell, Washington; Acuson, Sequoia 512, Siemens, Mountain View, California; Toshiba Aplio XG, Toshiba Medical Systems Corporation, Tochigi-Ken, Japan; GE Logiq 9, General Electric Corporation, Waukesha, Wisconsin) to obtain longitudinal and transverse gray-scale and color Doppler ultrasound scans of the abdomen, by using the graded-compression technique.[16] All studies included full abdominal ultrasound scanning and a localized study of right lower quadrant.

The ultrasound scanning results were immediately read by the diagnostic imaging staff on weekdays or the fellow on-call during evenings, nights, and weekends as positive, negative, or equivocal (non-diagnostic) for appendicitis. Although the fellows also received input into their interpretations from the staff the next day, the original interpretation was used for the study analysis because these are also used for clinical decisions.

Ultrasound scanning results were considered to be positive for appendicitis when there was a finding of a non-compressible appendix with an outer diameter in any portion ≥6 mm, appendicolith, hyperechoic periappendiceal fat, loss of echogenic submucosal layer, increased blood flow of the appendix on color Doppler ultrasound scanning, and periappendiceal collections seen in the absence of a visualized abnormal appendix.[17] Ultrasound scanning results were considered to be negative when an entire normal appendix was identified. Equivocal images were those in which the appendix was only partially visualized, had normal measurements with inflammatory signs, had borderline measurements (6 mm diameter) without inflammatory signs, or was not visualized in the absence of periappendiceal collections.[4]

The ultrasound scanning readers were blinded to the presenting clinical details and to the potential predictors of inaccurate ultrasound scanning results. All study ultrasound scans initially read by the fellows were reviewed within 24 hours by a staff radiologist on duty who was not part of the study, but the management of the patient was based on the initial interpretation. The ED staff and fellows subsequently managed the participating patients with the aid of a surgical consultation and the initial ultrasound scanning interpretation, without knowledge of the definition of ultrasound scanning accuracy. At this point, the decision was made to either proceed with surgery, discharge the patient home, or to admit the child. Children in whom the diagnosis of appendicitis was uncertain after the screening ultrasound scanning and a brief reassessment underwent a second ultrasound scanning, a CT, or both, at the discretion of the surgeon. Most CTs were done when the surgeon felt the discrepancy between clinical findings and the preceding ultrasound scanning dictated the need to clarify the diagnosis further.

One month later, the research assistants reviewed the electronic patient charts for secondary outcomes, for histological findings in the removed appendices, and for delayed diagnosis of appendicitis. All patients who did not undergo surgery were also telephoned at this time to ensure appendicitis was not diagnosed at another institution.

Definitions

The final diagnosis of appendicitis was based on the histological evidence of such at surgery and classified as perforated or non-perforated.[18] The pathologists were blinded to the clinical details and to the ultrasound scanning results. Final diagnosis of no appendicitis was based on either a normal pathological examination of the appendix or on finding no appendicitis at follow-up. True positive ultrasound scanning results were those interpreted as positive for histologically confirmed appendicitis. True negative ultrasound scanning results were interpreted as not showing appendicitis

confirmed either histologically or by lack of subsequent development of appendicitis. False-positive results consisted of ultrasound scans read as appendicitis, but with a negative appendectomy or no appendicitis on follow-up. False-negative results were cases in which the results of the first ultrasound scanning were negative, but the patient had appendicitis confirmed at surgery either in our hospital or later in another institution.

Diagnostically accurate ultrasound scanning results included the true-positive and true-negative examinations. Inaccurate ultrasound scanning results were images with false-positive or false-negative interpretations and those with equivocal readings. An ultrasound scanning examination lacking appendix visualization or having the aforementioned non-diagnostic features cannot reassure the ED physician that appendicitis has been ruled out[12] and is not helpful in management. Therefore, we have classified these cases as equivocal in interpretation and inaccurate in outcome and considered them as either false-positive or false-negative results. On the basis of the "worst-case scenario," equivocal ultrasound scanning in a child later found to have confirmed appendicitis was considered to be a false-negative result (because it did not identify appendicitis), and an equivocal case found not to have appendicitis histologically or on follow-up was considered to be a false-positive result (because the ultrasound scanning did not rule-out appendicitis).[4]

Outcome Measures

On the basis of the initial ultrasound scanning interpretation, the patients were classified in groups of those with diagnostically accurate and inaccurate ultrasound scanning. Before the study, we also determined several potential predictors of inaccurate ultrasound scanning. These included age, sex, body mass index for age percentiles (BMI-FAP),[19] duration of abdominal pain, white blood cell count, Faces Pain Score–Revised score,[20-22] estimated clinical probability of appendicitis on a visual analogue scale (0-100%), and the ultrasound operator type/experience (sonographer versus fellow). The BMI-FAP represents the best available measure of obesity in the pediatric population because the BMI estimate in a child compared with other growing children varies with age. The clinical probability of appendicitis was based on the overall clinical impression (history, examination, laboratory data) and classified by the ED staff as very unlikely (<20%), unlikely (20%-39%), neither likely nor unlikely (40%-59%), likely (60%-79%), and very likely (≥80%). The Faces Pain Score-Revised represents the most popular pediatric pain measurement tool found to be valid in the ED setting[23] in children ≥4 years of age.

Secondary outcome measures included the proportion of children with a definitive diagnostic management decision (defined as surgery or discharge home versus admission), proportion of prolonged ED stays in 12 hours, and the rate of subsequent imaging within 7 days in the accurate and inaccurate ultrasound scanning groups.

Statistical Analysis

The sample size was calculated to obtain reliable estimates for predictors of inaccurate ultrasound scanning results, with the overall frequency of inaccurate ultrasound results at our institution of 50% (unpublished preliminary data). A minimum of 10 "events" should be available per candidate predictor variable to obtain relatively stable estimates in a regression analysis.[24] For the 8 possible predictors that we investigated, we needed 80 inaccurate cases, and therefore a total of 160 patients had to be enrolled. Assuming that 10% of the patients would refuse to participate, 5% would have poor command of the English, 5% would not meet eligibility requirements, and 5% would be lost to follow-up, we adjusted the sample size to 213. Because we subsequently found the proportion of inaccurate ultrasound scanning results to be closer to 40%, we increased the sample size to 260.

The primary analysis used multivariable logistic regression to identify the relationship between the inaccuracy of the screening ultrasound scanning results and the 8 potential predictors listed previously. The probability of the inaccuracy of the ultrasound scanning results for each predictor was calculated by using the fitted logistic model. A two-tailed χ^2 or Fisher exact test was used to compare relevant proportions, and a Student *t* test was used for comparison of continuous variables in the diagnostically accurate and inaccurate groups. For each diagnostic test performance index such as sensitivity, specificity, positive and negative predictive values, and accuracy, relevant 95% confidence intervals (CI) were also computed.

Results

Of the 672 children who underwent ultrasound scanning for suspected appendicitis during the study period, 320 were screened, 24 were missed, and 328 were not approached because of a lack of study coverage. Of the 320 families approached for the study, 263 (82%) were enrolled, 14 refused participation, 39 met exclusion criteria, and 4 parents did not speak English. The non-approached population arrived during a similar time of day, was of similar age, and had a comparable rate of appendicitis to the approached cohort (103 of 352 or 29.3% versus 99 of 320 or 30.9%).

Of the 263 participating patients, 99 (37 %) had appendicitis. Three children had alternate surgical diagnoses, and 161 children had other medical illnesses. A total of 93 children were surgically treated: 87 (94%) had histologically proven appendicitis, 3 had alternate surgical diagnoses (splenic torsion in 1 and ovarian cyst torsion in 2), and 3 had medical diagnoses (omental infarction in 1 and reactive lymphoid hyperplasia in 2). One hundred nineteen children (45%) were admitted to hospital.

Ninety-five (36%) initial ultrasound scans were interpreted as positive for appendicitis, 76 (29%) were interpreted as negative, and 92 (35%) were considered equivocal. The diagnostic test performance of the screening ultrasound scanning is depicted in the **Figure**. Of the 92 patients with equivocal ultrasound scanning results, 13 (14.1%) had

appendicitis and 79 did not. In this group, the appendix was not adequately visualized in 78 cases (84.8%). In the 79 equivocal cases without appendicitis classified as having false-positive results, the appendix was not visualized in 56 (71%), was inadequately visualized in 11 (13.9%), had borderline measurements in 10 (12.7%), and was measured as normal with surrounding inflammatory changes in 2 (2.5%) children. Of the 13 equivocal cases with appendicitis classified as having false-negative results, the appendix was not fully seen in 11 (84.6%) and had borderline measurements in 2 (15.4%).

The screening ultrasound scanning had a sensitivity rate of 86.9% (95% CI, 78.6%-92.8%), a specificity rate of 46.3% (95% CI, 38.5%-54.3%), a positive predictive value of 49.4% (95% CI, 41.8%-57.1%), a negative predictive value of 85.4% (95% CI, 76.3%-92.0%), and accuracy rate of 61.6% (95% CI, 55.4%- 67.5%). A total of 162 ultrasound scans (61.6%) were diagnostically accurate for the final diagnosis of appendicitis, and 101 (38.4%) were inaccurate. There were no statistical differences in these two groups for sex, pain duration, Faces Pain Score-Revised, or the imaging operator/reader (**Table I**). Children with an inaccurate ultrasound scanning interpretation were significantly older, had a lower white blood cell count, had a higher BMI-FAP, and had a lower estimated clinical probability of appendicitis than their counterparts with accurate ultrasound scanning results (**Table I**).

We identified 2 independent predictors of inaccurate ultrasound scanning results: children with BMI-FAP ≥85th percentile (cutoff determined as per published definition of overweight/obese status[19] and a receiver operating characteristic curve of BMI and inaccurate ultrasound scanning results) and children with a clinical probability of appendicitis ≤50% (cutoff determined from a receiver operating characteristic curve of clinical probability of appendicitis and inaccurate ultrasound scanning results). These children were 2 and 2.4 times, respectively, as likely to have inaccurate ultrasound scanning results as their counterparts without these characteristics (**Table II**). Patients with both predictors were 2.5 times as likely to have inaccurate ultrasound scanning results as their counterparts without these features (**Table II**). The expected probability of inaccurate ultrasound scanning results in children with predictors alone and in combination is summarized in **Table II**. Because some children with a clinical probability of appendicitis <20% and >80% may have undergone ultrasound scanning because of extra caution rather than necessity, the analysis was repeated with this population excluded. The results were virtually identical.

Children with inaccurate screening ultrasound scanning results had a significantly lower proportion of definitive treatment (discharge home or surgery without observation, admission, or second imaging), more prolonged hospital stays, and a much higher proportion of subsequent imaging compared with their accurately imaged counterparts (**Table III**).

Of the 263 participating patients, 56 (21.6%) underwent a second imaging: 26 children underwent a second ultrasound scanning only, 17 underwent CT only, and 13 underwent both. A total of 4 of 80 children (5%) without the aforementioned predictors underwent CT, as compared with 26 of 183 children (14.2%) with predictors (P = .03). The diagnostic performance of second imaging is summarized in the **Figure**. Of the 39 repeat ultrasound scans, 36 (92%) correctly ruled-in/ruled-out appendicitis. All the CT results were diagnostically accurate.

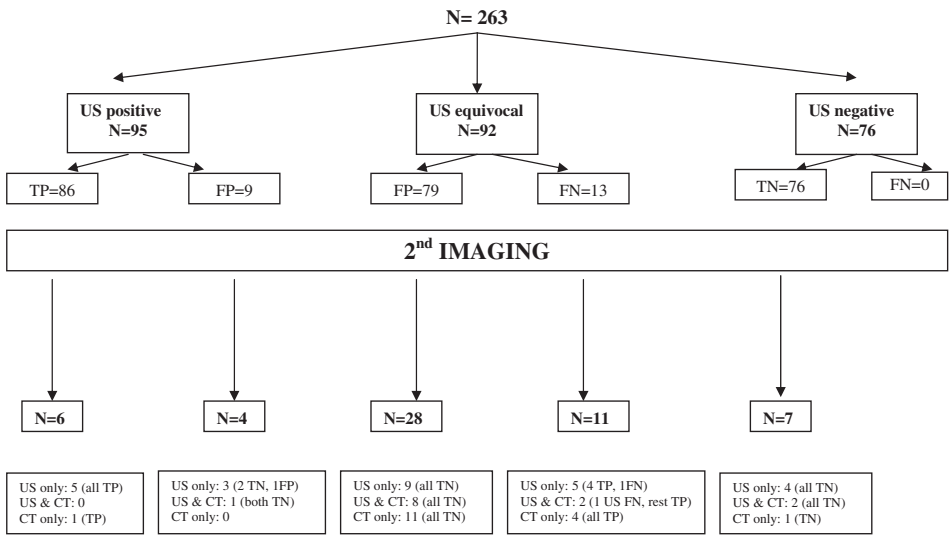

Figure. Diagnostic performance of the screening ultrasound scanning and subsequent imaging.

Table I. Characteristics of patients with accurate and inaccurate ultrasound scanning examination results

Characteristic	Accurate ultrasound n = 162	Inaccurate ultrasound n = 101	95% CI for differences
Age, years*	9.7 ± 3.6	10.6 ± 3.3	0.07-1.73
Male (%)	92 (56.8%)	47 (46.3%)	–21.5%-2.0%
BMI-FAP ≥85th percentile	38 (23.5%)	38 (37.6%)	2.5%-25.5%
Duration of pain, hours*	47.0 ± 53.7	53.2 ± 62.1	–8.6-20.9
White blood cell count*	13.3 ± 6.3	11.3 ± 4.9	–3.5-–0.5
Faces Pain Scale–Revised*	5.5 ± 2.6	5.0 ± (2.7)	–1.16-0.17
CPA ≤50 %, unlikely/highly unlikely (%)	80 (49.4%)	70 (69.3%)	8.1%-31.8%
Imaging operator (sonographer vs fellow)	73 (45.1%)	37 (36.6%)	–20.6%-3.7%
Imaging Interpreter (staff vs fellow)	54 (33.3%)	34 (33.6%)	–12.1-11.4

*Mean ± SD.

Of the 75 lean children with appendicitis, 66 were identified with the screening ultrasound scan, an additional 4 were identified with the second ultrasound scan, 2 cases were confirmed with a clinical reassessment only, and 3 children (4%) needed CT. Thus, the sensitivity of the screening ultrasound scan with either a second ultrasound scan or a clinical reassessment in this subpopulation was 72 of 75 or 96%. In the lean group without appendicitis (n = 112), the specificity of this pathway was 102 of 112 or 91%—58 cases were ruled out with the screening ultrasound scan, an additional 12 with the second ultrasound scan, 32 patients only required a clinical re-examination, and appendicitis was ruled out with CT in 10 children. In contrast, 3 of 24 or 12.5% obese children with appendicitis required CT, and 21 were identified via the aforementioned route. In the obese children without appendicitis (n = 52), the specificity rate of this pathway was 42/52 or 81%—8 cases were correctly ruled out with the screening ultrasound scan, an additional 8 cases were ruled out with the second ultrasoundscan, abdominal pain disappeared in another 16 cases (clinical re-examination only), and 10 patients (19%) required CT. In all lean children with suspected appendicitis, the diagnostic accuracy of the screening ultrasound scan followed by a second ultrasound scan or a clinical re-examination in ruling in/ruling out appendicitis was 174 of 187 or 93%. In contrast, only 83% of obese children (63/76) benefited from this pathway (95% CI for the difference, 0.01-0.19; $P = .012$).

Discussion

On the basis of the available preliminary evidence, a clinical policy of the American College of Emergency Physicians recommends that ultrasound scanning be considered as the initial imaging modality to diagnose suspected appendicitis.[25] As a result, many children in whom the diagnosis of appendicitis is suspected undergo screening ultrasound scanning, despite its lower sensitivity compared with CT.[26] We have demonstrated that this screen alone is frequently not helpful, particularly in children who are obese and have a low clinical probability of appendicitis. However, when followed by a clinical reassessment or a second ultrasound scan, appendicitis can be accurately identified or ruled out in most of children with BMI <85th percentile. Consideration should be given to not performing ultrasound scanning in obese children, as previously alluded to by Taylor and others.[15,27-28]

Although the sensitivity of the screening ultrasound scan was comparable with that in other pediatric studies,[29] its diagnostic accuracy was below that reported previously.[29] The reason for our findings lies in our definition of equivocal ultrasound scanning results, designed to reflect their unhelpful nature and to highlight this commonplace diagnostic difficulty.[26] Because these equivocal ultrasound scanning results did not rule in/rule out appendicitis, they were classified as inaccurate. Had we handled the equivocal ultrasound scanning results according to the "best case scenario" (ie, classified them as true-positive or true-negative as per final diagnosis of appendicitis), the sensitivity rate would be 100%, the specificity rate would be 94.5%, and the accuracy rate would be 96.6%. However, we felt this would not have reflected clinical reality because the equivocal ultrasound scanning results not only lacked benefit, but they have clearly negatively affected the outcomes. Very few of the earlier studies have specifically addressed this issue. For example, one team classified ultrasound scanning with non-visualized normal appendices as having negative results, and their few equivocal ultrasound scanning results were not defined.[4]

Table II. Adjusted odds ratios for independent predictors of inaccurate ultrasound scanning examination results

Number of predictors	n	n inaccurate	OR of inaccurate ultrasound	95% CI	Estimated probability of inaccurate ultrasound	95% CI
BMI-FAP ≥85th percentile	76	38	1.98	1.14-3.46	0.51	0.35-0.68
CPA ≤50%	150	70	2.37	1.40-4.03	0.51	0.38-0.63
BMI ≥85th percentile & CPA ≤50%	43	25	2.48	1.28-4.78	0.61	0.44-0.75
BMI <85th percentile & CPA ≤ 50%	107	45			0.42	0.33-0.52
BMI ≥85th percentile & CPA >50%	33	13			0.42	0.25-0.61
BMI <85th percentile & CPA >50%	80	18			0.23	0.14-0.33

Table III. Clinical outcomes in children with accurate and inaccurate ultrasound scanning examinations

Outcome	Accurate US n = 162	Inaccurate US n = 101	95% CI for the difference
Definitive management (surgery/discharge) on the basis of screening US (%)	137 (84.6%)	68 (67.3%)	−28.0%-−6.5%
Prolonged stay in emergency department >12 hours (%)	14 (8.6%)	40 (39.6%)	20.5%-41.4%
Appendicitis (%)	86 (53.1%)	13 (12.9%)	−50.3%-−30.1%
Perforated appendicitis (%)	24 (14.8 %)	4 (4.0 %)	−17.5%-−4.2%
Second imaging (%)	13 (8.0%)	43 (42.6%)	24.0%-45.2%
CT as second imaging (%)	4 (2.5%)	26 (25.7%)	14.4%-32.1%

US, Ultrasound scanning; *CT,* computed tomography.

Earlier studies have also identified the BMI as a factor affecting ultrasound scanning accuracy.[15,30] One small study concluded that obese adults should forego ultrasound scanning because of its poor accuracy.[30] Hormann et al studied children and also came to this conclusion, but only studied 14 overweight children, none of whom had appendicitis, and recommended that a larger study be done.[15] Increased thickness of the adipose tissue both increases the distance between the ultrasound scanning transducer beam and leads to limited compressibility of the appendix,[30] which compromises visualization of the appendix in obese individuals.

CT introduces a small but significant CT-related risk of a radiation-induced malignancy in children.[31] Because even a single CT is not without risks, its use must be limited. Contrary to the evidence that the most cost-effective method of imaging pediatric appendicitis is to start with an ultrasound scanning study and follow each negative ultrasound scanning result with a CT scan,[32] CT clarified the diagnosis in very few of our lean participants. Virtually all second ultrasound scans were diagnostically accurate, possibly aided by disease progression in the intervening interval between the first and second examinations in some children.

At the start of this study, the published diagnostic appendicitis scores had major limitations.[33,34] Although we were unable to apply Goldman's recently validated Pediatric Appendicitis Score to our data,[35] our CPA visual analog scale represents real-life diagnostic estimates, similar to the one used in the study by Garcia-Pena.[4] All enrolled children had right-lower quadrant tenderness and a Pediatric Appendicitis Score ≥2, so children at negligible risk of appendicitis did not participate.

This study comes from a single center with a considerable expertise in pediatric ultrasound scanning, likely comparable with that of other pediatric hospitals. Therefore, our high rate of non-diagnostic screening ultrasound scanning may well represent the "best-case scenario," because many children are seen at non-pediatric facilities. Although our results should be generalizable to other pediatric hospitals, they likely have poor applicability to children seen at general EDs, where our colleagues with expertise in adult imaging may lack equivalent proficiency in pediatric ultrasound scanning, and to pediatric hospitals failing to provide a 24-hour, 7-day-a-week ultrasound scanning service. In these settings, the rate of inaccuracy may be even higher, and more CT may be necessary. A question also arises whether the high proportion of patients not approached to participate could have caused a selection bias. However, the comparable rates of appendicitis in the approached and non-approached cohorts make the possibility of selection bias unlikely.

In conclusion, screening ultrasound scanning for pediatric appendicitis has highly suboptimal diagnostic accuracy, particularly in obese children with a low likelihood of appendicitis. Consideration should thus be given to not routinely performing ultrasound scanning in this subpopulation. However, screening ultrasound scanning followed by a second ultrasound scan or a clinical reassessment offers high sensitivity, specificity, and diagnostic accuracy in lean children at pediatric EDs with suspected appendicitis. The choice of imaging should ultimately depend on local resources, level of expertise, and outcomes.[27] ■

Submitted for publication Oct 5, 2009; last revision received Apr 26, 2010; accepted Jul 21, 2010.

References

1. Janik JS, Firor HV. Pediatric appendicitis. A 20-year study of 1640 children at Cook County (Illinois) Hospital. Arch Surg 1979;114:717-9.
2. Rettenbacher T, Hollerweger A, Gritzmann N, Gotwald T, Schwamberger K, Ulmer H, et al. Appendicitis: should diagnostic imaging be performed if the clinical presentation is highly suggestive of the disease?[see comment]. Gastroenterology 2002;123:992-8.
3. Pieper R, Kager L, Nasman P. Acute appendicitis: a clinical study of 1018 cases of emergency appendectomy. Acta Chir Scand 1982;148:51-62.
4. Garcia Pena BM, Mandl KD, Kraus SJ, Fischer AC, Fleisher GR, Lund DP, et al. Ultrasonography and limited computed tomography in the diagnosis and management of appendicitis in children. JAMA 1999;282:1041-6.
5. Puylaert JB. Acute appendicitis: US evaluation using graded compression. Radiology 1986;158:355-60.
6. Hahn HB, Hoepner FU, Kalle T, Macdonald EB, Prantl F, Spitzer IM, et al. Sonography of acute appendicitis in children: 7 years experience. Pediatr Radiol 1998;28:147-51.
7. Kessler N, Cyteval C, Gallix B, Lesnik A, Blayac PM, Pujol J, et al. Appendicitis: evaluation of sensitivity, specificity, and predictive values of US, Doppler US, and laboratory findings. Radiology 2004;230:472-8.
8. Puig S, Staudenherz A, Felder-Puig R, Paya K. Imaging of appendicitis in children and adolescents: useful or useless? A comparison of imaging techniques and a critical review of the current literature. Semin Roentgenol 2008;43:22-8.
9. Kaiser S, Frenckner B, Jorulf HK. Suspected appendicitis in children: US and CT—a prospective randomized study. Radiology 2002;223:633-8.
10. Even-Bendahan G, Lazar I, Erez I, Guttermacher M, Verner M, Konen O, et al. Role of imaging in the diagnosis of acute appendicitis in children. Clin Pediatr 2003;42:23-7.
11. Blebea JS, Meilstrup JW, Wise SW. Appendiceal imaging: which test is best? Semin Ultrasound CT MR 2003;24:91-5.
12. Sivit CJ. Imaging the child with right lower quadrant pain and suspected appendicitis: current concepts. Pediatr Radiol 2004;34:447-53.
13. Sivit CJ, Applegate KE, Stallion A, Dudgeon DL, Salvator A, Schluchter M, et al. Imaging evaluation of suspected appendicitis in a pediatric population: effectiveness of sonography versus CT. AJR Am J Roentgenol 2000;175:977-80.

14. Emil S, Mikhail P, Laberge JM, Flageole H, Nguyen LT, Shaw KS, et al. Clinical versus sonographic evaluation of acute appendicitis in children: a comparison of patient characteristics and outcomes. J Pediatr Surg 2001;36:780-3.
15. Hormann M, Scharitzer M, Stadler A, Pokieser P, Puig S, Helbich T. Ultrasound of the appendix in children: is the child too obese? Eur Radiol 2003;13:1428-31.
16. Puylaert JB, Rutgers PH, Lalisang RI, de Vries BC, van der Werf SD, Dorr JP, et al. A prospective study of ultrasonography in the diagnosis of appendicitis. N Engl J Med 1987;317:666-9.
17. Sivit CJ, Siegel MJ, Applegate KE, Newman KD. When appendicitis is suspected in children. Radiographics 2001;21:247-62; questionnaire 88–94.
18. Crawford J. The gastrointestinal system. In: Cotran RS, Stanely R, Kumar V, eds. Robbins pathologic basis of disease. 5th ed. Philadelphia: W.B. Saunders Company; 1994. p. 822-3.
19. Flegal KM, Wei R, Ogden C. Weight-for-stature compared with body mass index-for-age growth charts for the United States from the Centers for Disease Control and Prevention. Am J Clin Nutr 2002;75:761-6.
20. Belville RG, Seupaul RA. Pain measurement in pediatric emergency care: a review of the faces pain scale-revised. Pediatr Emerg Care 2005;21:90-3.
21. Bieri D, Reeve RA, Champion GD, Addicoat L, Ziegler JB. The Faces Pain Scale for the self-assessment of the severity of pain experienced by children: development, initial validation, and preliminary investigation for ratio scale properties. Pain 199;41:139–150.
22. Hicks CL, von Baeyer CL, Spafford PA, van Korlaar I, Goodenough B. The Faces Pain Scale-Revised: toward a common metric in pediatric pain measurement. Pain 2001;93:173-83.
23. Bulloch B, Tenenbein M. Validation of 2 pain scales for use in the pediatric emergency department. Pediatrics 2002;110:e33.
24. Harrell FE, Jr, Lee KL, Matchar DB, Reichert TA. Regression models for prognostic prediction: advantages, problems, and suggested solutions. Cancer Treat Rep 1985;69:1071-7.
25. Howell JM. Clinical policy: evaluation and management of suspected appendicitis. American College of Emergency Physicians; January 2010. Available at: http://m.acep.org/MobileArticle.aspx?id=47471&coll_id=615&parentid=740. Accessed Apr 14, 2010.
26. Han TI. Improved sonographic visualization of the appendix with a saline enema in children with suspected appendicitis. J Ultrasound Med 2002;21:511-6.
27. Taylor GA. Suspected appendicitis in children: in search of the single best diagnostic test. Radiology 2004;231:293-5.
28. Grayson DE, Wettlaufer JR, Dalrymple NC, Keesling CA. Appendiceal CT in pediatric patients: relationship of visualization to amount of peritoneal fat. AJR Am J Roentgenol 2001;176:497-500.
29. Doria AS, Moineddin R, Kellenberger CJ, Epelman M, Beyene J, Schuh S, et al. US or CT for diagnosis of appendicitis in children and adults? A meta-analysis. Radiology 2006;241:83-94.
30. Josephson T, Styrud J, Eriksson S. Ultrasonography in acute appendicitis. Body mass index as selection factor for US examination. Acta Radiol 2000;41:486-8.
31. Brenner D, Elliston C, Hall E, Berdon W. Estimated risks of radiation-induced fatal cancer from pediatric CT. AJR Am J Roentgenol 2001; 176:289-96.
32. Wan MJ, Krahn M, Ungar WJ, Caku E, Sung L, Medina LS, et al. Acute appendicitis in young children: cost-effectiveness of US versus CT in diagnosis—a Markov decision analytic model. Radiology 2009;250:378-86.
33. Impellizzeri P, Centonze A, Antonuccio P, Turiaco N, Cifala S, Basile M, et al. Utility of a scoring system in the diagnosis of acute appendicitis in pediatric age. A retrospective study. Minerva Chir 2002;57:341-6.
34. Bond GR, Tully SB, Chan LS, Bradley RL. Use of the MANTRELS score in childhood appendicitis: a prospective study of 187 children with abdominal pain. Ann Emerg Med 1990;19:1014-8.
35. Goldman RD, Carter S, Stephens D, Antoon R, Mounstephen W, Langer JC. Prospective validation of the pediatric appendicitis score. J Pediatr 2008;153:278-82.